Journal of
HYPERTENSION RESEARCH
www.hypertens.org/jhr

Case Report
J Hypertens Res (2018) 4(4):156–162

# A hypotension case report

**Georgiana Savu[1*], Sebastian Onciul[2], Corneliu Iorgulescu[1], Oana Tautu[1], Maria Dorobantu[1,2]**

[1]Emergency Clinical Hospital Bucharest, Romania
[2]University of Medicine and Pharmacy 'Carol Davila', Cardiology Department, Clinical Emergency Hospital Bucharest, Romania

Received: October 20, 2018, Accepted: December 7, 2018

## Abstract

The case report is about a 79 years old patient admitted in our clinic with severe episodes of LOC appeared at 1-5 minutes after standing up from supine position and resulted in complete recovery. A VVI permanent pacemaker had been implanted 9 years ago for complete atrio-ventricular block. The pacemaker was upgraded to DDD after 9 years, as the patient developed heart failure. He was permanently urinary sondated with a Demeure after benign prostatic hyperplasia surgery. At clinical examination, the blood pressure in supine position was 120/80mmHg and after three minutes, in orthostatic position, the blood pressure drops at 70mmHg. The 24 hours blood pressure monitoring showed that the maxim value of blood pressure was 231/110mmHg and the minimum about 77/46mmHg. A diagnostic of severe orthostatic hypotension with supine hypertension was established and considered as the most probable aetiology of the recurrent episodes of LOC. Here are dissected the causes of syncope and LOC according to the age of the patient, to his comorbidities and the whole clinical picture. So baroreceptors failure, pacemaker syndrome, antihypertension drugs and cardiac diseases were discussed in this case. We also report the possibility of a Shy Drager Syndrome. In our case two important symptoms correspond to this disease. Our patient had orthostatic hypotension without an objective cause and urinary incontinence (he is permanently urinary sondated with a Demeure). We also presented the possibilities of treatment in this case and the evolution of the patient and his prognostic according with the severe episodes of OH.

**Keywords:** orthostatic hypotension, syncope, pacemaker syndrome

A 78 years old male patient was admitted for several episodes of loss of consciousness (LOC) in the last four years, which had been more frequent in the last five months with 2-5 episodes per day. All of these episodes of LOC appeared at 1-5 minutes after standing up from supine position and resulted in complete recovery. The patient had a history of arterial hypertension and high blood lipids. A VVI permanent pacemaker had been implanted 9 years ago for complete atrio-ventricular block. The pacemaker was upgraded to DDD after 9 years, as the patient developed heart failure. He was known with coronary artery disease, for which two drug

*Correspondence to: Dr. Georgiana Elena SAVU
Emergency Clinical Hospital Bucharest - Cardiology, Calea Floreasca 8, Bucharest, 014461, Romania.
Tel.:0742373239; e-mail:elenagsavu@yahoo.com

©The Author(s) 2018. This article is published with open access under the terms of the Creative Commons Attribution License.

eluting stents (DES) were implanted seven years ago on the right coronary artery and on the circumflex artery, respectively. He denied any anginal symptoms after revascularisation. He was permanently urinary sondated with a Demeure after benign prostatic hyperplasia surgery. His chronic medication consisted in: Clopidogrel 75mg od, Atorvastatin 10mg od, Amlodipine 5mg od.

**Clinical exam:** His heart rate was 65 beats/minute. There were no signs of cardiac congestion and the lungs were clear to auscultation. The blood pressure in supine position was 120/80mmHg and after three minutes, in orthostatic position, the blood pressure drops at 70mmHg.

**The blood tests** showed a mild anemia (Hb 10.9g/dl) and hypokaliemia (K 3.8mmol/L).

**Electrocardiogram** on admission showed atrial cardiostimulation rhythm, native ventricular activity, with negative T waves in lateral territory (V5-V6). Figure 1

**The echocardiography** revealed left ventricular hypertrophy, predominantly of the posterior wall (14mm), without enlargement of the left ventricle and a normal systolic function (55% ejection fraction). The transmitral Doppler pattern showed a grade 1 diastolic dysfunction with normal filling pressures (figure 2 and figure 3) and a dilated left atrium (60ml/m$^2$). No significant valve disease was identified and there was no evidence of increased pulmonary artery pressure.

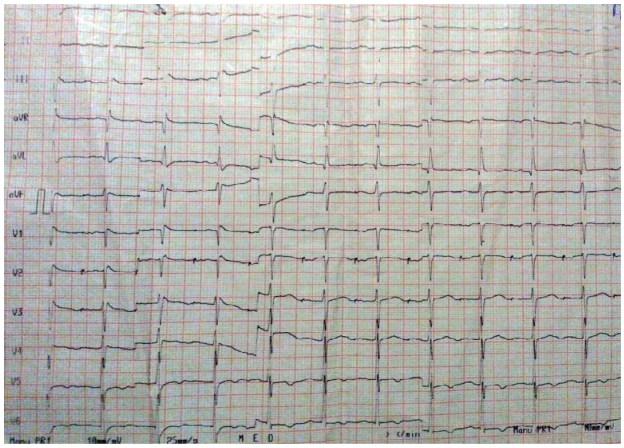

Figure 1. Electrocardiogram showing atrial cardiostimulation rhythm, native ventricular activity, with negative T waves in lateral territory.

**The 24 hours blood pressure monitoring** showed that the maxim value of blood pressure was 231/110mmHg at 4:00 p.m and the minimum about 77/46mmHg at 08:45 a.m., with a constant heart rate between 70-87 beats/minute). Figure 4

A diagnostic of severe orthostatic hypotension with supine hypertension was established and considered as the most probable aetiology of the recurrent episodes of LOC.

Consequently, both non-pharmacological and pharmacological treatment was initiated in our patient. Lifestyle changes were explained to the patient (drinking enough water, elevating the head of the bed; avoiding crossing legs when sitting and standing up slowly) and Amlodipine was initially stopped. Fludrocortisone (0.1mg per day to 0.3mg per day) was introduced in an attempt to increase the blood pressure. As no response was obtained, Midrodrin was subsequently added.

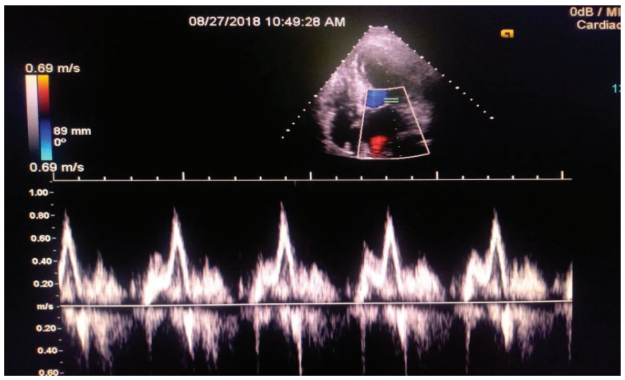


Figure 2. Transmitral Doppler pattern showing a grade 1 diastolic dysfunction with normal filling pressures.

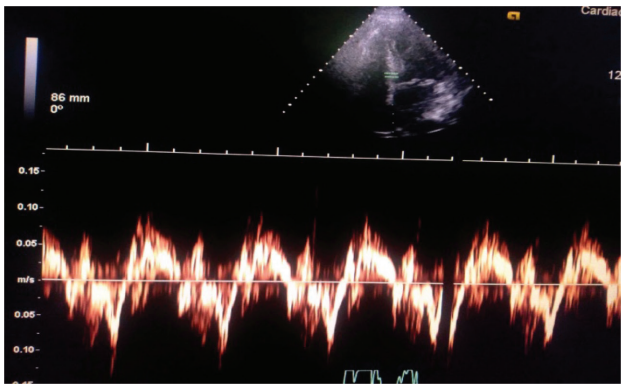


Figure 3. Transmitral Doppler pattern showing a grade 1 diastolic dysfunction with normal filling pressures.

*©The Author(s) 2018*

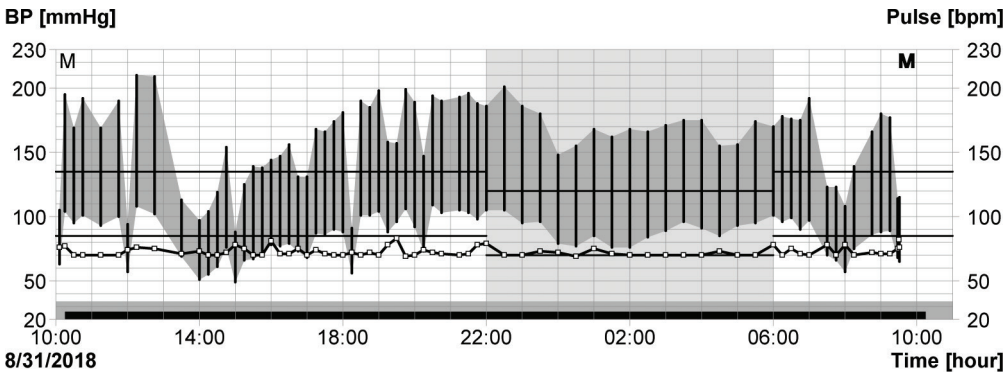


Figure 4. 24 hours blood pressure monitoring

(2.5 mg per day to 30mg per day). As no improvement in blood pressure values was obtained, the treatment with midodrine was eventually stopped. The discharge medication consisted in Fludrocortisone (0.3 mg per day) added to Clopidogrel and Atorvastatin.

At 4 months follow-up, the patient remained symptomatic with severe orthostatic intolerance, with an impaired quality of life.

## Discussion

We report the case of a patient with a long history of multiple episodes of LOC, a scenario not uncommonly encountered in the daily clinical practice. In this case, the clinical description of LOC episodes by both the patient and the family pointed to the syncope to be the cause of LOC episodes, and made relatively easy the differentiation from other causes of transient

LOC such as epilepsy. ESC guideline on syncope defines syncope as a transient LOC associated with the inability to maintain postural tone, due to cerebral hypoperfusion, characterized by three important elements: rapid onset, short duration and spontaneous complete recovery. This episode does not require any electrical or chemical cardioversion. [1]

Syncope is a common medical condition that affects 5-30% of the general population.[2] Framingham Study found that 822 of 7814 men and women (11 percent) who were followed for an average of 17 years reported an apparent syncopal episode. The prevalence of syncope increases with age, 19% of the individuals older than 80 years having reported a syncopal episode.[1]

### Dissecting the aetiology of syncope

By further exploring the aetiology of syncope, both cardiac and non-cardiac conditions should be looked for.

The cardiac syncope can be caused by neurological pathways (vaso-vagal syncope, situational syncope, syncope resulted from the hypersensibility of carotid sinus or other atypical forms), by orthostatic hypotension or by cardiac diseases. The prognostic of the syncope depends on the cause.[1] The cardiogenic syncope has a hight rate of mortality. [3]

The most common causes are the neurological pathways, especially in elderly, like our patient, that implies neurocardiac reflexes that lead to bradycardia and hypotension. It can happen very suddenly, with a complete recovery. They can occur in response of emotional situations, for example seeing needles, blood, or when some organs are stimulated like defecation, swallowing, micturition. The diagnose of reflex syncope is more likely using Tilt Test or after the other causes are excluded.[4]

Cardiogenic syncope is defined as a syncopal episode caused by a cardiovascular disease: bradyarrhythmias/tachyarrhythmias, pacemaker malfunction, valvular disease(severe aortic stenosis, mitral stenosis), myocardial infarction/ischemia, hypertrophic cardiomyopathy, arrhytmogenic right ventricle cardiomyopathy, pericardial disease, corrected congenital heart defects.[5] Our patient had a history of stable coronary artery disease, however there was no evidence of myocardial ischemia after revascularisation.

In this case it is important to remember that the patient was implanted with a VVI pacemaker for a complete atrioventricular block 9 years ago.


*©The Author(s) 2018*

Nine years after pacemaker implantation, he developed heart failure symptoms and several episodes of LOC, which were interpretted as pacemaker syndrome; consequently the decision at that time was to upgrade the pacemaker to DDD. The pacemaker syndrome is induced more often by VVI pacemakers, which can create an atrioventricular dyssinchrony. So the atrium will contract against closed tricuspid valves and that increases the pressure in the right atrium and in the upper veins, so there is stimulatted the vasodepressor response with vasodilatation and hypotension. In this situation, to improve the atrioventricular conduction and to decrease the ventricular pacing, the pacemaker was upgraded at DDD, without a sinificant BP improvement. So, the pacemaker syndrome wasn't the cause of the othostatic BP symptoms.

Orthostatic hypotension (OH) is defined by American Autonomic Society and the American Academy of Neurology as a >20mmHg decrease in systolic BP or >10mmHg in the diastolic BP within three minutes of changing the position from supine to orthostatic position.[6] The 2018 ESC guideline of syncope adds to the basic definition of OH the decrease of systolic BP to <90mmHg. This absolute threshold of 90mmHg of systolic BP is useful in patients with supine BP lower than 110mmHg. The isolated drop of diastolic BP is not a frequently employed OH diagnostic criteria in clinical practice.

OH can be caused by a baroceptors dysfunction. In orthostatic position, the muscle contraction pumps the blood from the lower parts of the body to the heart and the venous valves prevent the return of the blood to the lower extremities. The autonomic nervous system also responds to the orthostatic position with vasoconstriction and tachycardia. Thus in healthy individuals these mechanisms help preventing OH. [6]

However, in patients with diabetes, various types of polyneuropathies, Parkinson's disease, or in the elderly baroceptors failure is frequently encountered and is associated with OH and consequently with a worse prognosis. [7] Our patient isn't a diabetic one, but is eldery.

The 2018 ESC Guidelines of Syncope syntetise the causes of orthostatic hypotension: (Table 1-Modified after[4]).

Elderly patients are more likely to develop OH because they loose more frequently the baroreceptor sensitivity and the vagal tonus and their adaptive system are damaged like the venous return, the muscles contraction, the ventricular filling. So they can't have the ability to compensate for changing position in several minutes. Elderly subjects have also problems with thirst perception and water and salt conservation and that can increase the risk of dehydration and hypotension.[7]

Another frequent condition that can determine OH are: the drugs like tricyclic antidepressants, α1-blockers, antiparkinsonian, antihypertensives such as diuretics, vasodilators, symphatolytics and diseases that affect the cardiac filling, the venous return or the muscular system.

Our patient has no neurological treatment, but only an antihypertensive drug, a calcium blocker, that was rapidly removed from the medications, with the persisting of the orthostatic hypotension. So the medication cannot be a real cause of the orthostatic hypotension.

The Shy Drager Syndrome or multiple system atrophy is a degenerative disease of the central nervous system with autonomic dysfunction that include:

Table 1. The 2018 ESC Guidelines of Syncope mention the causes of orthostatic hypotension (modified from (4)).

| | | |
|---|---|---|
| 1. | Drug induced OH | Vasodilators, diuretics, phenothiazine, antidepressants |
| 2. | Volume depletion | haemorrhage, diarrhoea, vomiting, etc |
| 3. | Primary autonomic failure (neurogenic OH) | pure autonomic failure, multiple system atrophy, Parkinson's disease, dementia with Lewy bodies |
| 4. | Secondary autonomic failure (neurogenic OH) | diabetes, amyloidosis, spinal cord injuries, auto-immune autonomic neuropathy, paraneoplastic autonomic neuropathy, kidney failure |

©The Author(s) 2018

orthostatic hypotension, urinary incontinence, loss of sweating, impotence, rectal incontinence, tremor, spasticity, ataxia. It is associated with Parkinson's disease. The condition is called olivopontinecerebelarr desese when it dominates the celebellar symptoms and The Shy Drager Syndrome when autonomyc syptomes predominates[8]. In our case two important symptoms correspond to this disease. Our patient had orthostatic hypotension without an objective cause and urinary incontinence (he is permanently urinary sondated with a Demeure). To prove the autonomic implications of the disease, the plasma noradrenaline concentrations shoud be helpfull. For example, for the patient with autonomy dysfunction, the plasma noradrenaline concentrations are very low, but this investigation is not proved that is useful for the diagnose of the Shy Dragner Syndrome[8] and it was not performed in our clinic.

**Treatment**

Management of OH is very complex. First of all, the major priority is to increase the orthostatic blood pressure, without raising the supine blood pressure. It is very difficult to achieve this goal without the price of inducing a supine hypertension. It is important that our patient changes his lifestyle, trying to avoid the sudden movements and changing his lifestyle in order to minimize the risk of orthostatic stress. So it is important to expand the blood volume of our patient (the patient will drink at least 2 litres of liquids per day), to minimise the nocturia (by using a pillow or raising the bed by 10 to 20 degrees the rennin-angiotensin system will be activated), to avoid the pooling of the blood in lower extremities (by using abdominal binder and physical exercises more in horizontal position-isometrically contractions below the waist) and to stimulate a pressor response (500ml of cold water, via norepinephrine effect-increses the systolic blood pressure with more than 20mmHg).[9]

The second step is the pharmacological treatment. In the table below, the possibilities of medical treatment in orthostatic hypotension are presented. (table 2-modified after [10]).

In a cohort retrospective study with 1324 patients treated with fludrocortisone and 797 patients treated with midodrine. in 2017 was showed that fludrocortisone has an increase risk of hospitalization compared with midodrine, in particular in patients with cardiovascular history. [11] Fludrocortisone increases the BP by stimulating renal sodium reabsorption and expanding

Table 2. Treatment options in orthostatic hypotension (modified from (10)).

| Mechanism | Type of drugs |
|---|---|
| Reducing salt loss | Mineralocorticoids (fludrocortisone) |
| Reducing nocturnal polyuria | Vasopressin-2-receptor agonist (desmopressin) |
| Vasoconstriction-sympathetic | Directly on resistance vessels (Midodrine, noradenaline, clonidine)<br>Indirectly on resistance vessels (Ephedrine, tiramine with monoamino oxidase inhibitors) |
| Vasoconstriction-nonsympathetic | Vasopressin 1-agonist (terlipressin) |
| Preventing vasodilatation | Prostaglandin synthetase inhibitors (indomethacin)<br>Dopamine receptor blockade (Metoclopramide, Domperidone)<br>Beta-adrenoreceptors blockade (Propranolol) |
| Preventing postprandial hypotension | Adenosine receptor blockade (Caffeine) |
| Increasing cardiac output | Betablockers with intrinsic sympathetic activity (pindolol)<br>Dopamine agonists (ibopamine) |
| Increasing red cells mass | Recombinant erythropoietin |

 *©The Author(s) 2018*

plasma volume. It is important to know that the effect of fludrocortisone depends very much on the underlying disease. So in the elderly, fludrocortisone has a higher risk to increase the BP.[12] In a small study, on patients with orthostatic hypotension, was showed that fludrocortisone increases the BP in supine position and this effect is associated with increased peripheral-vascular resistance, not with plasma extending.[13]

Midodrine is a vasoconstrictive agent that actions directly on the resistance of the vassels increasing BP in orthostatic position, but without any benefits on supine position and with risk ok hypertension, piloerection, urinary retention, pruritis, etc. There are not enough evidence for using midodrin to treat OH.[14]

In our case, the patient also sleeps using two pillows and abdominal binder. It was interrupted the antihypertensive drug(calcium bloccant) and it was tried to increase the blood pressure by introducing Fludrocortisone, a synthetic mineralocorticoid analog that stimulates the reabsorbation of renal sodium, increasing the intravascular volume (short time effect) and stimulating angiotensine II (long term effect).[15] The treatment was initiated with 0.1mg od, 1/2cp two times per day, and after several days, the dose was increased up to 0.1mg od, 1cp, two times per day, without a singnificant response. It was monitored the potassium level and the overload signs. Midrodrin, alpha 1 adrenergic agonist, was addited to the treatment. This is a short acting pressor that can increase the blood pressure in standing position for about 2 hours and it;s used when the patient is in supine position because the BP will increase too much.[15] In this case, the dose was increased from 2,5mg od per day to 30mg od per day. In hole this time, there was no significant improvement in the patient evolution. Furthermore, the BP was increasing day by day, with a maximum systolic blood pressure at 200mmHg and a minimum at 80/50mmHg in orthostatic position. In this moment, the treatment with midodrine was stopped because there was no benefits.

### Evolution and prognostic

The life of this patient changes completely. His prognostic depends very much on his comorbidities, on his medical condition, but generally is poor. This patient has a higher risk of fractures, so orthopedic complications are requent and affect the quality of life of these patients. In a recent study that included 363 patients after 18 years old with hypotension due to Parkinson disease, multiple system atrophy and pure autonomic failure was demonstrated that the quality of life was affected in 59% of the patients. More than 87% reported that this medical condition affects their daily activities such physical activities, working, travelling). [16]

On follow-up, the patient remains with a severe othostatic intolerance, dependent more of the time of supine position with an affected quality of life, despite de medical efforts. He learned to protect by standing a couple of minutes besides the bed and avoiding sudden movements.

After three months of treatment, the patient complains about higher values of BP, more often in the evening, in supine position, when BP increases up to 180/190mmHg. So to fele more comfortable, he tries to use Nitroderm patches during the night, that did not seem to help a lot.

Probably we should adjust the treatment of this patients by using an antihypertensive drug with a lower risk of orthostatic hypotension, such as ACE-inhibitors, angiotensin II receptor antagonists, dihydropyridine calcium channel blockers in the evening, when the patient stays in supine position for many hours.

Considering the benign prostatic hypertrophy of the patient, it can be useful to try an alpha- blocant that will reduce also the BP. It is showed that in elderly, diabetic patients with OH, alfuzosin and tamsulosin have a lower risk of OH.[17]

**In conclusion**, OH is a relatively common condition which severely impairs the quality of life. The treatment of the condition is very challenging, especially in the cases with associated supine hypertension. Titration of medication doses and individual timing of administration may be the key for improving patient symptoms.

## Conflict of interest

The authors confirm that there are no conflicts of interest.

©The Author(s) 2018

## Bibliography


1. da Silva RMFL. Syncope: epidemiology, etiology, and prognosis. Front Physiol [Internet]. Frontiers Media S.A.; 2014 Dec 8;5:471. Available from: https://www.ncbi.nlm.nih.gov/pubmed/25538626
2. Low PA. Prevalence of orthostatic hypotension. *Clin Auton Res*. Germany; 2008 Mar;18 Suppl 1:8–13.
3. Seger JJ. Syncope evaluation and management. *Texas Hear Inst J* [Internet]. 2005;32(2):204–6. Available from: https://www.ncbi.nlm.nih.gov/pubmed/16107115
4. Brignole M, Moya A, de Lange F, Deharo J-C, M Elliott P, Fanciulli A, et al. 2018 ESC Guidelines for the diagnosis and management of syncope. Vol. 39, European Heart Journal. 2018.
5. Guimarães RB, Essebag V, Furlanetto M, Yanez JPG, Farina MG, Garcia D, et al. Structural heart disease as the cause of syncope. *Brazilian J Med Biol Res = Rev Bras Pesqui medicas e Biol*. 2018;51(4):e6989.
6. Bradley JG, Davis KA. Orthostatic hypotension. *Am Fam Physician*. United States; 2003 Dec;68(12):2393–8.
7. Arnold AC, Shibao C. Current concepts in orthostatic hypotension management. *Curr Hypertens Rep*. 2013 Aug;15(4):304–12.
8. Rehman HU. Multiple system atrophy. *Postgrad Med J* [Internet]. 2001 Jun 1;77(908):379 LP-382. Available from: http://pmj.bmj.com/content/77/908/379.abstract
9. Figueroa JJ, Basford JR, Low PA. Preventing and treating orthostatic hypotension: As easy as A, B, C. *Cleve Clin J Med*. 2010 May;77(5):298–306.
10. Mathias CJ, Kimber JR. Treatment of postural hypotension. *J Neurol Neurosurg & Psychiatry* [Internet]. 1998 Sep 1;65(3):285 LP-289. Available from: http://jnnp.bmj.com/content/65/3/285.abstract
11. Grijalva CG, Biaggioni I, Griffin MR, Shibao CA. Fludrocortisone Is Associated With a Higher Risk of All-Cause Hospitalizations Compared With Midodrine in Patients With Orthostatic Hypotension. *J Am Heart Assoc*. England; 2017 Oct;6(10).
12. Veazie S, Peterson K, Ansari Y, Chung KA, Gibbons CH, Raj SR, et al. Fludrocortisone for orthostatic hypotension. *Cochrane Database Syst Rev* [Internet]. John Wiley & Sons, Ltd; 2017;(12). Available from: https://doi.org//10.1002/14651858.CD012868
13. Chobanian A V, Volicer L, Tifft CP, Gavras H, Liang CS, Faxon D. Mineralocorticoid- induced hypertension in patients with orthostatic hypotension. *N Engl J Med*. United States; 1979 Jul;301(2):68–73.
14. Parsaik AK, Singh B, Altayar O, Mascarenhas SS, Singh SK, Erwin PJ, et al. Midodrine for orthostatic hypotension: a systematic review and meta-analysis of clinical trials. *J Gen Intern Med*. 2013 Nov;28(11):1496–503.
15. Shibao C, Lipsitz LA, Biaggioni I. Evaluation and treatment of orthostatic hypotension. *J Am Soc Hypertens*. 2013;7(4):317–24.
16. Claassen DO, Adler CH, Hewitt LA, Gibbons C. Characterization of the symptoms of neurogenic orthostatic hypotension and their impact from a survey of patients and caregivers. *BMC Neurol*. England; 2018 Aug;18(1):125.
17. Milazzo V, Stefano CD, Servo S, Crudo V, Fulcheri C et al. Drugs and Orthostatic Hypotension: Evidence from Literature. *J Hypertens*. 2012;1:104.




*©The Author(s) 2018*