Journal of
HYPERTENSION RESEARCH
www.hypertens.org/jhr

Case Report

J Hypertens Res (2016) 2(4):153–159

Severe hypertension in a young patient. What is the cause?

Oana Tautu[1,2], Camelia Acatrinei[1], Viorel Poalelungi[2], Maria Dorobantu[1,2]

[1] "Carol Davila" University of Medicine and Pharmacy, Bucharest, Romania
[2] Cardiology Department, Clinical Emergency Hospital Bucharest, Bucharest, Romania

Received: December 7, 2016, Accepted: December 14, 2016

Abstract

Obstructive sleep apnea syndrome (OSAS) is recognized nowadays as an exceedingly common cause of secondary arterial hypertension. Reduction in arterial oxygen pressure during each apneic episode activates reflexes that result in increased sympathetic and renin-angiotensin-aldosterone system activity, and consequently increased blood pressure and heart rate values after each apneic episode. We present a case of a young male hypertensive patient referred for a cardiologic evaluation due to an abnormal routine electrocardiogram recorded on admission in the neurology department for a second ischemic stroke. Due to the fact that the patient is young and hypertensive, a secondary cause of arterial hypertension is suspected. Following nighttime recordings of airflow, oxygen saturation, blood pressure and electrocardiogram, the diagnosis of obstructive sleep apnea syndrome is confirmed and suggested as the underlying cause of arterial hypertension. Further investigations reveal the cardiovascular complications of the obstructive sleep apnea syndrome and the secondary arterial hypertension: left ventricular hypertrophy, aortic aneurism requiring surgical treatment, ventricular arrhythmias. The two reported ischemic strokes might also be considered among the obstructive sleep apnea complications, superimposed with the smoker and obese status of the patient. Obstructive sleep apnea is a common cause of secondary arterial hypertension among young hypertensive patients and should be suspected especially in obese and/or active smoker patients as well as in diabetic patients and in those with COPD and/or severe CKD. If undiagnosed and untreated, OSA lead to uncontrolled hypertensive disease and target organ damage and an early onset of major cardiovascular events in young hypertensive patients.

Keywords: obstructive sleep apnea syndrome, hypertension, young, cardiovascular events

Introduction

Obstructive sleep apnea syndrome, defined through a combination of at least five episodes of obstructive breathing per hour of sleep and symptoms such as choking or gasping during sleep, recurrent awakening, unrefreshing sleep and daytime sleepiness, is recognized nowadays as an exceedingly common cause of secondary arterial hypertension (1). The elevated blood pressure values are a result of recurrent nocturnal hypoxemia, which impairs the sympathetic nerve activity as well as the renin-angiotensin-aldosterone system. Continuous positive airway pressure treatment results in a lowering of blood pressure values,

* Correspondence to: Oana TAUTU, MD, PhD
Clinical Emergency Hospital Bucharest, Calea Floreasca no.8, sector 1, postal code 014461, Bucharest, Romania.
Tel./fax: 004021-3170108; e-mail: dr.tautu@yahoo.com

both systolic and diastolic, both during wakefulness and sleep.

Case report

A 46-year-old male with a previous medical history of hypertension (diagnosed at the age of 42 and treated daily with 50mg of metoprolol, 10mg of enalapril and 5 mg of amlodipine) and a previous ischemic stroke 8-years ago, was referred for an evaluation in the cardiology department due to the presence of ventricular bigeminy on the electrocardiogram recorded on admission in the neurology department, accusing abrupt onset of weakness and numbness in the arm and leg on the left side of the body, being diagnosed with acute ischemic stroke in the territory supplied by the right middle cerebral artery.

The physical examination revealed no significant changes, apart from the increased body weight - 38.9 kg/m^2 body-mass index accounting for second degree obesity, with regular heart sounds at a heart rate of 86/min, a blood pressure value of 135/85mmHg, with no heart or vascular murmurs and without signs of pulmonary or systemic congestion, symmetric bilateral pulsatile arteries.

The transthoracic echocardiography revealed a concentric hypertrophied left ventricle without abnormal regional wall movement with preserved systolic function (LVEF=55%), mild diastolic dysfunction (impaired relaxation pattern) with normal filling pressures, and no criteria for pulmonary hypertension and no pericardial effusion. Furthermore, an ascending aortic aneurysm was identified with moderate aortic regurgitation (Figure 1).

In this context, a thoracic computed tomography was performed, revealing an ascending aortic aneurysm of 6 cm maximum dimension at the level of the aortic root, without evidence of aortic dissection (Figure 2).

In order to investigate the previously documented ventricular bigeminy, a 24-hour electrocardiogram (ECG) Holter monitoring was performed. This revealed sinus rhythm superimposed with monomorphic premature ventricular complexes accounting for approximately 11% of the total heart beats. The ventricular extrasystoles (VES) were organized as ventricular bigeminy, couplets, triplets and non-sustained ventricular tachycardia. No other arrhythmias or ST segment

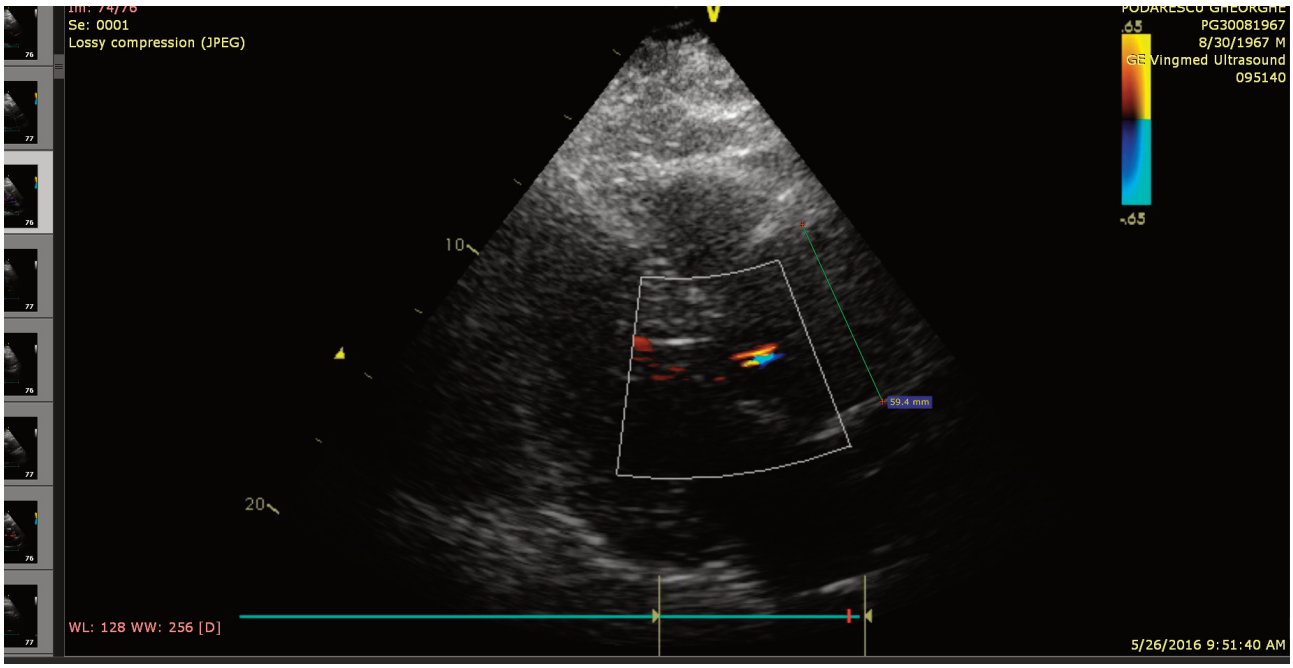

Figure 1. Transthoracic echocardiography. PLAX view: concentric LV hypertrophy (IVS = 12mm, LV posterior wall - 13mm), dilated ascending aorta (59mm) with mild regurgitation at color Doppler examination. PLAX: parasternal long axis; LV: left ventricle; IVS: intraventricular septum.

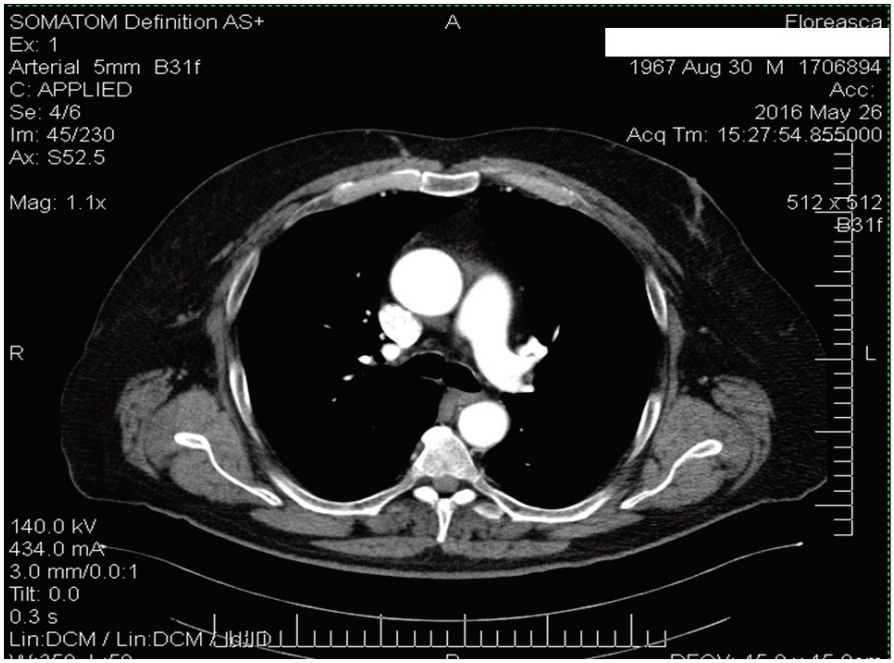

Figure 2. Thoracic computer tomography.

or T wave changes were identified (Figure 3-5). The majority of the VES were recorded during night-time.

Taking into account that hypertension onset was at an early age, a diagnosis of secondary arterial hypertension was suspected. In this respect, the most common causes of secondary arterial hypertension (renal parenchymal disease, renal artery stenosis, primary aldosteronism) were excluded due to the normal values of the laboratory tests and paraclinic evaluation.

Considering the night-time symptoms such as intermittent snoring and disturbed sleep, the presence of obesity in active smoker and the increased occur-

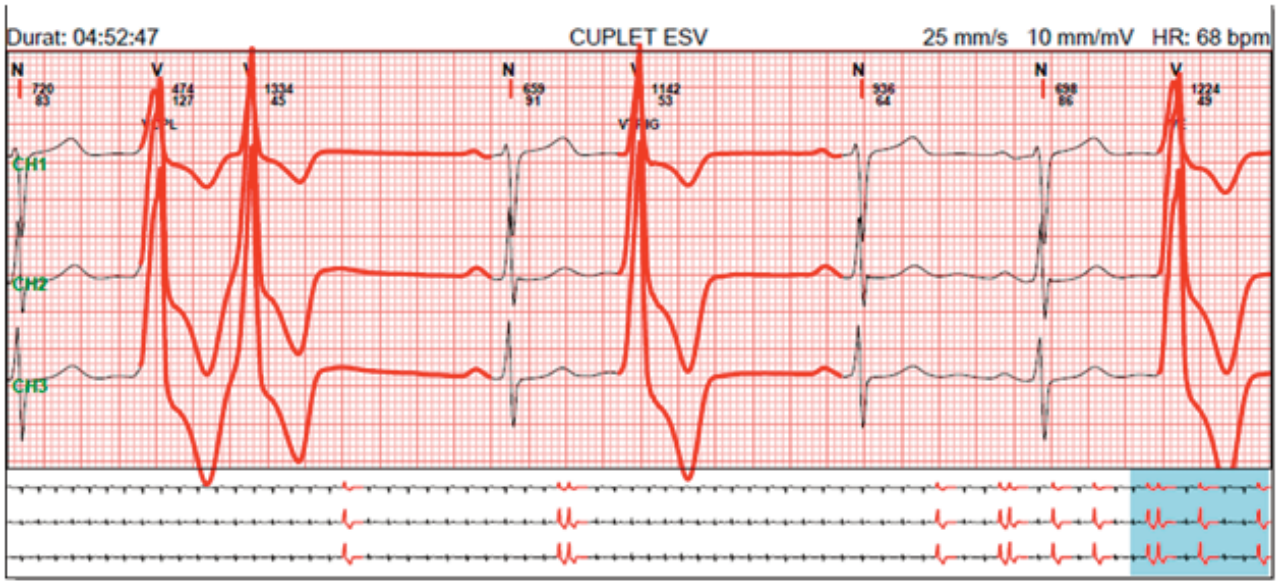

Figure 3. Couplets on 24-hour ECG Holter monitoring.

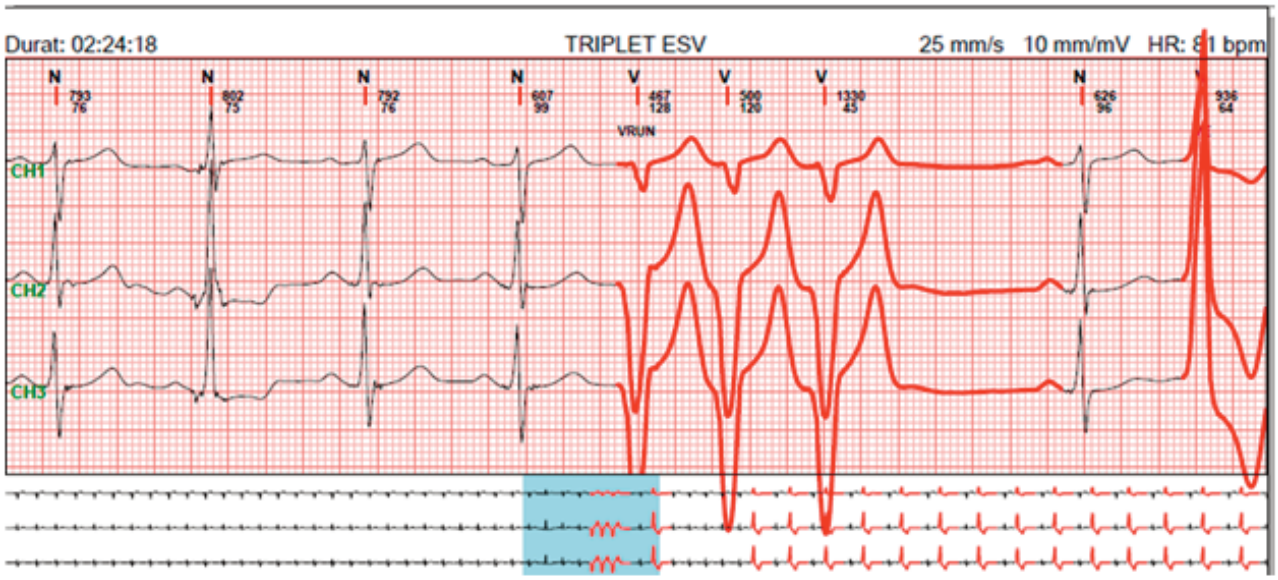

Figure 4. Triples on 24-hour ECG Holter monitoring.

rence of VES during sleep period, a diagnosis of obstructive sleep apnea syndrome was speculated. Therefore, a polysomnography (recordings of airflow, oxygen saturation, blood pressure and electrocardiogram) was performed during nighttime. These revealed the presence of a severe sleep apnea syndrome with average apnea-hypopnea index (AHI) of 37.6 (Figure 6).

The coronary angiography evaluation, performed in order to exclude the ischemic origin of ventricular arrhythmias, revealed no significant coronary lesions.

The following diagnosis was established: aortic aneurism without evidence of aortic dissection and mild aortic regurgitation; hypertensive heart disease with preserved LV systolic function, monomorphic ventricular extrasystolic systematized arrhythmia (couplets,

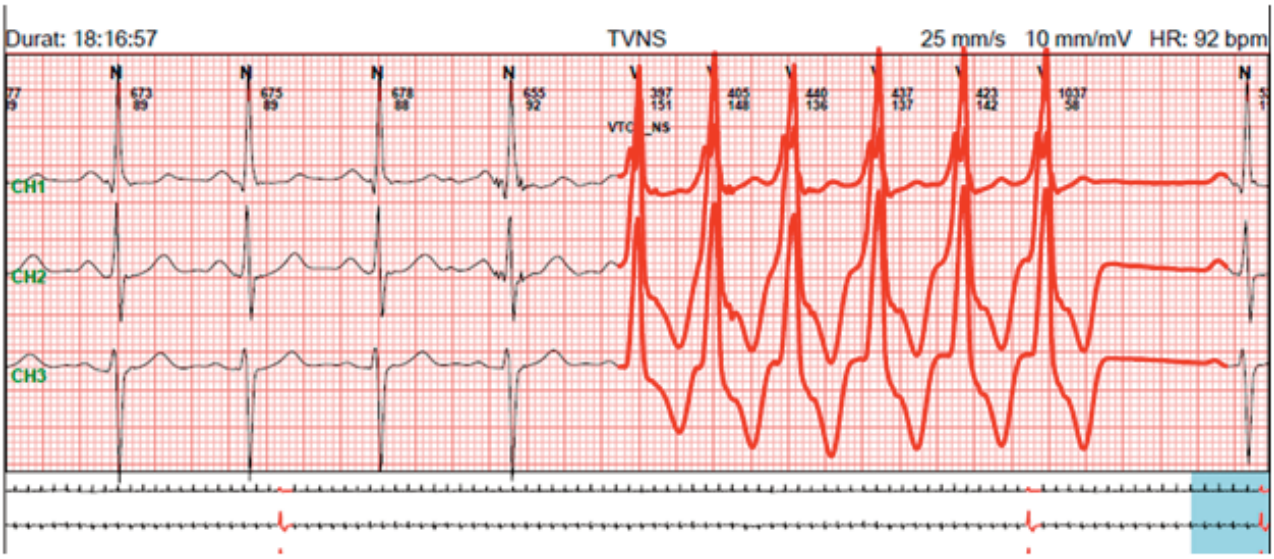

Figure 5. Non-sustained ventricular tachycardia on 24-hour ECG Holter monitoring.

	Code	Index (#/hour)	Total Number of Events	Mean duration (sec)	Max duration (sec)	Events by Position	
						Supine (#)	Non-Supine (#)
Central Apneas	CA	1.8	16	17.4	35	5	11
Obstructive Apneas	OA	7.7	70	24.8	150.5	37	33
Mixed Apneas	MA	0.4	4	19.5	29	1	3
Hypopneas	HY	11.5	105	23.2	57.5	66	39
Total		**21.4**	195	23.2	150.5		
					Time in Position	174.1	371.9
					AHI in Position	37.6	13.9

Figure 6. Diagnostic Polysomnography.

triplets and non-sustained ventricular tachycardia) grade III secondary arterial hypertension and severe obstructive sleep apnea syndrome requiring nighttime CPAP.

Treatment with beta-blocker (bisoprolol), angiotensin-receptor blocker and non-dihidropiridinic receptor blocker fixed combination (olmesartan + amlodipine) targeting an heart rate of 60bpm and a BP value of 120/70mmHg, statine (atorvastatine), antiplatelet therapy (ASA) as well as and night-time CPAP was initiated.

Treatment with positive airway pressure resulted in improvement of sleep related symptoms and a significant decrease of ventricular arrhythmias on the 24-hour electrocardiogram monitoring and a decrease in AHI from 37.6 to 26.9 (Figure 7).

The evolution during hospitalization was towards improvement. As a consequence, the patient was discharged after 5 days. The recommended medical treatment at discharge was: antiplatelet medication (clopidogrel 75 mg q.d.), beta-blocker (bisoprolol 5 mg b.i.d.), calcium channel blockers and sartan fixed combination (amlodipine + olmesartan 5/20 mg q.d.), statine (atorvastatin 40 mg q.d.) and nourotropic medication (piracetam 600 mg q.d.) together with

Clinician:
Administrator, New

Compliance Information 5/25/2016 - 5/31/2016

A-Flex™

Compliance Summary

Date Range	5/25/2016 - 5/31/2016 (7 days, 5 days excluded)
Days with Device Usage	2 days
Days without Device Usage	0 days
Percent Days with Device Usage	100.0%
Cumulative Usage	8 hrs. 59 mins. 31 secs.
Maximum Usage (1 Day)	4 hrs. 31 mins. 2 secs.
Average Usage (All Days)	4 hrs. 29 mins. 45 secs.
Average Usage (Days Used)	4 hrs. 29 mins. 45 secs.
Minimum Usage (1 Day)	4 hrs. 28 mins. 29 secs.
Percent of Days with Usage >= 4 Hours	100.0%
Percent of Days with Usage < 4 Hours	0.0%
Total Blower Time	9 hrs. 32 secs.
Auto CPAP Summary	
Auto CPAP Mean Pressure	5.6 cmH2O
Auto CPAP Peak Average Pressure	5.9 cmH2O
Average Device Pressure <= 90% of Time	7.1 cmH2O
Average Time in Large Leak Per Day	1 hrs. 21 mins. 30 secs.
Average AHI	26.9

Figure 7. Polysomnography with CPAP titration.

nighttime CPAP therapy, recommendation non-pharmacologic treatment and a referral to cardiovascular surgery for surgical treatment of the aneurism of the ascending aorta.

Discussion

Secondary arterial hypertension is defined as increased systemic blood pressure due to an identifiable cause, renal parenchymal disease, renal artery stenosis, primary aldosteronism and obstructive sleep apnea being the most common diseases leading to this form or arterial hypertension (2) (3).

Obstructive sleep apnea (OSA) consists of obstructive breathing events with complete upper airway obstruction (i.e. residual air flow below 20% of the preceding period of stable breathing or reduction in air flow more than 80%), each event lasting at least 10s. As far as obstructive sleep apnea syndrome (OSAS) is concerned, it is defined through a combination of at least five obstructive breathing episodes per hour during sleep (apneas, hypopneas, respiratory effort related arousal) and symptoms such as excessive daytime sleepiness that is not better explained by other factors, choking or gasping during sleep, recurrent awakenings from sleep, unrefreshing sleep, daytime fatigue, impaired concentration. A distinction should be made between OSA as a laboratory diagnosis and OSAS as a clinical syndrome, composed of OSA and the abovementioned symptoms (4).

It is widely recognized that untreated OSA has both short and long-term consequences on the cardiovascular system and a number of possible responsible mechanisms have been described.

First of all, reduction in arterial oxygen pressure during each apneic episode activates reflexes that result in increased sympathetic activity, and consequently increased blood pressure and heart rate values after each apneic episode (5). Furthermore, the vigorous respiratory efforts against the occluded airway lead to a decrease in intratoracic pressure and thus change the ventricular loading conditions as well as the autonomic cardiac modulation. Last but not least, the resistant arterial hypertension associated with OSA might be a consequence of increased aldosterone secretion and thus changes in the renin-angiotensin-aldosterone system (6).

As a result of the these changes in physiology, a number of cardiovascular complications have are related to untreated OSA, the association being more convincing for the subgroup of severe OSA (characterized by more than 30 episodes of apnea and hypopnea per hour of sleep).

Thus, OSA increases the risk of stroke independently of other cerebrovascular risk factors (7). It increases stiffness of large arteries and thus contributes to left ventricular remodeling, studies revealing that left ventricular hypertrophy is more prevalent in hypertensive patients without OSA, in normotensive patients with OSA, and even more in patients affected by both arterial hypertension and OSA (8). Furthermore, it promotes left ventricular dysfunction and progression towards congestive heart failure (9). There is also a correlation between OSA and arrhythmias, non-sustained ventricular tachycardia being one of the most prevalent arrhythmias related with this disorder (10).

The presented case confirms the abovementioned theories. A male patient is referred for cardiologic evaluation due to an abnormal routine electrocardiogram. Due to the fact that the patient is young and hypertensive, a secondary cause of arterial hypertension is suspected. Following nighttime recordings of airflow, oxygen saturation, blood pressure and electrocardiogram, the diagnosis of obstructive sleep apnea syndrome is confirmed and suggested as the underlying cause of arterial hypertension. Further investigations reveal the cardiovascular complications of the obstructive sleep apnea syndrome and the secondary arterial hypertension: left ventricular hypertrophy, aortic aneurism, ventricular arrhythmias. The two reported ischemic strokes might also be considered among the obstructive sleep apnea complications, superimposed with the smoker and obese status of the patient.

Conclusions

A cause of secondary arterial hypertension should be investigated in every young hypertensive patient.

Obstructive sleep apnea is a common cause of secondary arterial hypertension among young hypertensive patients and should be suspected especially in obese and/or active smoker patients as well as in dia-

betic patients and in those with COPD and/or severe CKD.

If undiagnosed and untreated, OSA as well as other causes of secondary HT, lead to the progression of uncontrolled hypertensive disease towards target organ damage and an early onset of major cardiovascular events in young hypertensive patients.

References

1. Clinical Guideline for the Evaluation, Management and Long-term Care of Obstructive Sleep Apnea in Adults. J Clin Sleep Med JCSM Off Publ Am Acad Sleep Med. 2009 Jun 15;5(3):263–76.
2. Members AF, Mancia G, Fagard R, Narkiewicz K, Redon J, Zanchetti A, et al. 2013 ESH/ESC Guidelines for the management of arterial hypertension. Eur Heart J. 2013 Jul 21;34(28):2159–219.
3. Rimoldi SF, Scherrer U, Messerli FH. Secondary arterial hypertension: when, who, and how to screen? Eur Heart J. 2013 Dec 23;eht534.
4. Parati G, Lombardi C, Hedner J, Bonsignore MR, Grote L, Tkacova R, et al. Position paper on the management of patients with obstructive sleep apnea and hypertension: joint recommendations by the European Society of Hypertension, by the European Respiratory Society and by the members of European COST (COoperation in Scientific and Technological research) ACTION B26 on obstructive sleep apnea. J Hypertens. 2012 Apr;30(4):633–46.
5. Charkoudian N, Rabbitts JA. Sympathetic Neural Mechanisms in Human Cardiovascular Health and Disease. Mayo Clin Proc. 2009 Sep;84(9):822–30.
6. Calhoun DA. Obstructive Sleep Apnea and Hypertension. Curr Hypertens Rep. 2010 Jun 1;12(3):189–95.
7. Capampangan DJ, Wellik KE, Parish JM, Aguilar MI, Snyder CRH, Wingerchuk D, et al. Is obstructive sleep apnea an independent risk factor for stroke? A critically appraised topic. The Neurologist. 2010 Jul;16(4):269–73.
8. Drager LF, Bortolotto LA, Figueiredo AC, Silva BC, Krieger EM, Lorenzi-Filho G. Obstructive sleep apnea, hypertension, and their interaction on arterial stiffness and heart remodeling. Chest. 2007 May;131(5):1379–86.
9. Somers VK, White DP, Amin R, Abraham WT, Costa F, Culebras A, et al. Sleep apnea and cardiovascular disease: an American Heart Association/american College Of Cardiology Foundation Scientific Statement from the American Heart Association Council for High Blood Pressure Research Professional Education Committee, Council on Clinical Cardiology, Stroke Council, and Council On Cardiovascular Nursing. In collaboration with the National Heart, Lung, and Blood Institute National Center on Sleep Disorders Research (National Institutes of Health). Circulation. 2008 Sep 2;118(10):1080–111.
10. Hersi AS. Obstructive sleep apnea and cardiac arrhythmias. Ann Thorac Med. 2010;5(1):10–7.